

**MORPHOMETRIC STUDY OF THE EFFECT OF  
HYPERVITAMINOSIS A ON THE SUBLINGUAL GLAND  
OF THE RAT**

*Ruberval A. Lopes,<sup>1</sup> José Renan V. da Costa,<sup>2</sup> Geraldo Maia  
Campos,<sup>3</sup> Sergio O. Petenusci<sup>4</sup> and Ana Maria Piccolo<sup>5</sup>*

**University of São Paulo, School of Pharmacy and Dentistry of  
Ribeirão Preto, Ribeirão Preto, São Paulo, Brazil**

**SUMMARY**

Hypervitaminosis A induces the following changes in the rat sublingual gland: smaller size acini with lower cells and smaller nuclei. The serous demilunes show smaller cells and nuclei. The striated ducts show smaller and disorganized cells with smaller nuclei. These data were confirmed by morphometric techniques.

---

Modified manuscript received: 27-12-79.

- 1 Professor, Department of Pathology of the School of Pharmacy and Dentistry of Ribeirão Preto, 14,100 Ribeirão Preto, São Paulo, Brazil.
- 2 Assistant Professor of the School of Pharmacy and Dentistry of Alfenas, Minas Gerais, Brazil.
- 3 Assistant Professor, Department of Pathology of the School of Pharmacy and Dentistry of Ribeirão Preto.
- 4 Assistant Professor of the Department of Physiological Sciences, School of Pharmacy and Dentistry of Ribeirão Preto.
- 5 Biologist fellow, Department of Pathology, School of Pharmacy and Dentistry of Ribeirão Preto.

## INTRODUCTION

Administration of continuous doses of vitamin A to rats induces degeneration of the acinar cells and granulous and striated ducts in the submandibular (1, 2) and sublingual (3) glands, as well as decreased amounts of sialic acid and hexosamines in the cytoplasm (4). These structural alterations have also been observed in the rat posterior lingual glands (5).

The purpose of this research was to study morphometrically the alterations observed in the sublingual gland of rats, after submitting the animal to hypervitaminosis A.

## MATERIAL AND METHODS

### *Animals*

Twenty male Wistar rats, weighing approximately 84.0 g, were divided into two groups of 10 animals each. The first group received intraperitoneal injections of 200 IU/g body weight of vitamin A (Arovit - Produtos Roche Químicos e Farmacêuticos S. A.) for a period of 10 days. The second group was similarly injected with saline. All animals had free access to water and a balanced ration (Ração para Animais de Laboratório, Anderson Clayton S. A. Indústria e Comércio) and water.

### *Dissection, Weighing, and Histological Techniques*

The animals were weighed daily and sacrificed at the end of the experiment (11th day) by ether inhalation. The submandibular and sublingual pairs of glands were dissected after exposure by a ventral incision in the neck region and skin separation, cleaned and separated. The adrenal glands were also removed.

The sublingual and adrenal glands were fixed in Bouin's liquid for 24 hours, weighed on a precision balance (Mettler), embedded in paraffin, cut into sections 7  $\mu$ m thick, and stained with hematoxylin - eosin.

### *Morphometric Techniques*

1. *Chalkley technique.* The Chalkley technique (6) was used to evaluate the area of glandular tissues on a percentage basis.

For this purpose, an eyepiece prepared with 5 standard points, and an immersion objective (100 x) were used; each standard point corresponded to the free end of the arrow, and the histological structure indicated (acini, connective tissue and ducts) was recorded individually. A determination was made of the number of times the selected structures were reached by the standard points, and 500 points were counted for each gland. The data gave the percentage of the area for each structure.

2. *Technique for the measurement of the acinar area.* Histological images, magnified 500 x, were projected on the screen of a Reichert Visopan, and the largest perpendicular diameters of 25 acini per animal were measured with the help of transparent graph paper. The area was calculated by the following formula:

$$A = \frac{\pi \cdot D_1 \cdot D_2}{4}$$

where A is the ellipse area,  $D_1$  the largest diameter, and  $D_2$  the smallest diameter.

*Karyometry:* In order to obtain the volumes of the serous demilunes and ducts cell nuclei of the sublingual gland, the sections were focused at the optical microscope with an immersion objective (100 x) to which a light camera (Reichert) was adapted. The nuclei were projected on vegetal paper at a final 1,140 x magnification. The outlines of the images obtained (50 per each gland of each animal from both groups) were drawn with a soft pencil. Only elliptical images were considered. The longest and shortest axis were measured in order to obtain the nuclear volume, and a third axis was obtained by the geometric average of the first two. The ellipsoid volume was calculated according to Valeri *et al.* (7) by the following formula:

$$V = 0,35341426 \cdot D_1 \cdot D_2 \cdot \sqrt{D_1 \cdot D_2}$$

where  $D_1$  and  $D_2$  represent the longest and shortest axis, respectively.

*Statistical technique:* The nonparametric Mann-Whitney test and the median test (8) were used to compare the data obtained for the two groups of animals studied.

## RESULTS

One of the most obvious alterations observed in vitamin A-treated animals was weight loss. Body weight of the controls varied between 85.3 g (first day of the experiment) and 112.6 g (11th day of the experiment), while that of the animals treated with excess vitamin A was between 82.7 g (first day) and 67.0 (11th day). The average glandular weights for the controls was 23.55 mg and for hypervitaminotic animals was 20.75 mg; increased sublingual weight/100 g body weight was also observed in the treated animals (Table 1), since body weight was reduced more intensely than glandular weight. Mean adrenal weight was 10.86 mg for the controls, and 19.58 mg for treated animals; increased adrenal weight/100 g body weight was also observed in the hypervitaminotic A animals (Table 1).

Histological examination of the sublingual gland of vitamin A-treated animals revealed smaller size acini with lower cells and smaller nuclei. The striated ducts had a disorganized appearance and their nuclei were smaller in size. The serous demilunes show smaller cells and nuclei, with less acidophilic cytoplasm (Figure 1).

Percentage and mean values of the data obtained by the Chalkley technique (6) for the sublingual gland structures selected for study (acini, connective tissue and ducts), both from hypervitaminotic animals and controls, are presented in Table 2. Analysis of the data in this Table reveals that the animals submitted to hypervitaminosis A showed percentage values equal to 76.44 for the acini, 19.28 for the connective tissue, and 4.28 for the ducts, while the values for the controls were 83.46, 9.84, and 6.70 for the same structures, respectively.

Vitamin A provoked decreased acini and ducts, with increased connective tissue in the sublingual glands of the treated animals when compared to the controls.

To complement the above data, acinar areas were measured in the sublingual gland, and the values are presented in Table 2.

Total mean demilune nuclear volume was  $91.29 \mu\text{m}^3$  for the controls, and  $81.11 \mu\text{m}^3$  for the treated rats (Table 2). To confirm these data, Figure 2 was constructed with the help of a logarithmic ruler to represent the frequency distribution of the nuclear volumes of the serous demilune cells in the glands of the control and hypervitaminotic animals. Analysis of this figure suggests a dislocation to the left of the median of the nuclear

TABLE 1

MEASUREMENTS OF SUBLINGUAL AND ADRENAL MASS IN ANIMALS SUBMITTED TO HYPERVITAMINOSIS A (T) AND IN CONTROLS (C)

| Groups | Mean weight of the two sublinguals (mg)* | Mean sublingual weight (mg)/100g body weight* | Adrenal weight (mg)*   | Adrenal weight (mg)/100g body weight* |
|--------|--|---|------------------------|---------------------------------------|
| C      | 23.55<br>( $\pm$ 0.97)                   | 20.82<br>( $\pm$ 0.71)                        | 10.86<br>( $\pm$ 0.45) | 10.09<br>( $\pm$ 0.55)                |
| T      | 20.75<br>( $\pm$ 0.84)                   | 31.15<br>( $\pm$ 1.36)                        | 19.58<br>( $\pm$ 0.36) | 28.21<br>( $\pm$ 1.00)                |

\* Statistically significant difference ( $\alpha = 0.05$ ) between treated and control groups.

volumes for the hypervitaminotic animals. This decreased median was confirmed by applying the median test. With the data from Table 3 a value of 15.40 was obtained for  $\bar{X}^2$ , which, when compared to the tabulated  $\chi^2$  value (3.84), led us to reject the possibility of these values being equal.

As shown in Table 2, the mean nuclear volumes of the striated duct cells of the sublingual gland were lower for hypervitaminotic animals ( $72.33 \mu\text{m}^3$ ) than for the controls ( $99.81 \mu\text{m}^3$ ).

Once Figure 3 was constructed, showing the frequency histograms for nuclear volumes of the striated duct cells, a dislocation to the left was observed for the median of the nuclear volumes of treated rats. This dislocation was also confirmed by the median test. With the data of Table 4 a value of 138.72 was obtained for  $\bar{X}^2$ , which, when compared to the tabulated value of  $\chi^2$  (3.84), led us to reject the possibility of these values being equal.

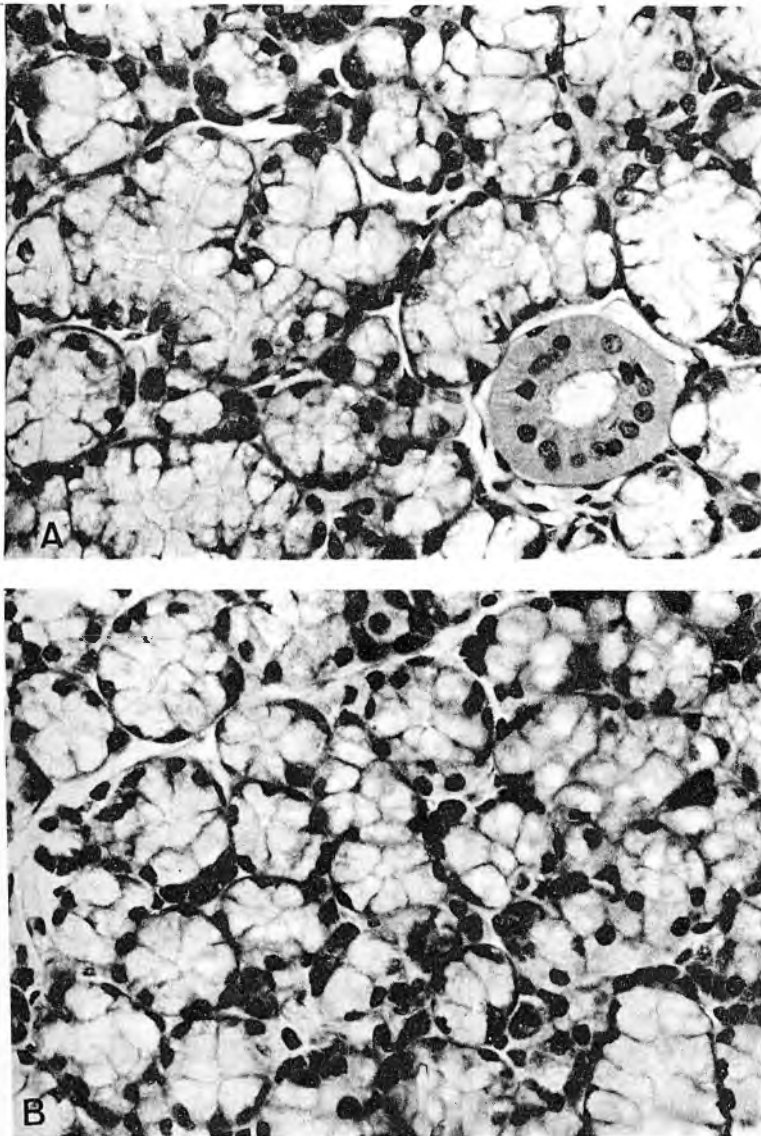


FIGURE 1

Histological picture of control (A) and hypervitaminotic (B) rat sublingual glands. Hematoxylin and eosin (200 x)

TABLE 2

RESULTS OF QUANTITATIVE ANALYSIS OF THE SUBLINGUAL GLAND IN CONTROL RATS (C) AND ANIMALS SUBMITTED TO HYPERVITAMINOSIS A (T): PERCENTAGE VALUES FOR ACINI, CONNECTIVE TISSUE, AND DUCTS, CELL NUCLEAR VOLUME, AND ACINAR AREA

| Groups | Percentage values for structures |                        |                       | Nuclear volume ( $\mu\text{m}^3$ ) |                        | Acinar area ( $\mu\text{m}^2$ )* |
|--------|----------------------------------|------------------------|-----------------------|------------------------------------|------------------------|----------------------------------|
|        | Acini*                           | Conjunctive*           | Ducts*                | Demilune*                          | Duct*                  |                                  |
| C      | 83.46<br>( $\pm$ 0.52)           | 9.84<br>( $\pm$ 0.39)  | 6.70<br>( $\pm$ 0.32) | 91.29<br>( $\pm$ 5.33)             | 99.81<br>( $\pm$ 5.08) | 1,904<br>( $\pm$ 93.92)          |
| T      | 76.44<br>( $\pm$ 0.31)           | 19.28<br>( $\pm$ 0.48) | 4.28<br>( $\pm$ 0.42) | 81.11<br>( $\pm$ 4.16)             | 72.33<br>( $\pm$ 3.38) | 1,267<br>( $\pm$ 57.04)          |

\* Statistically significant difference ( $\infty - 0.05$ ) between treated and control groups.

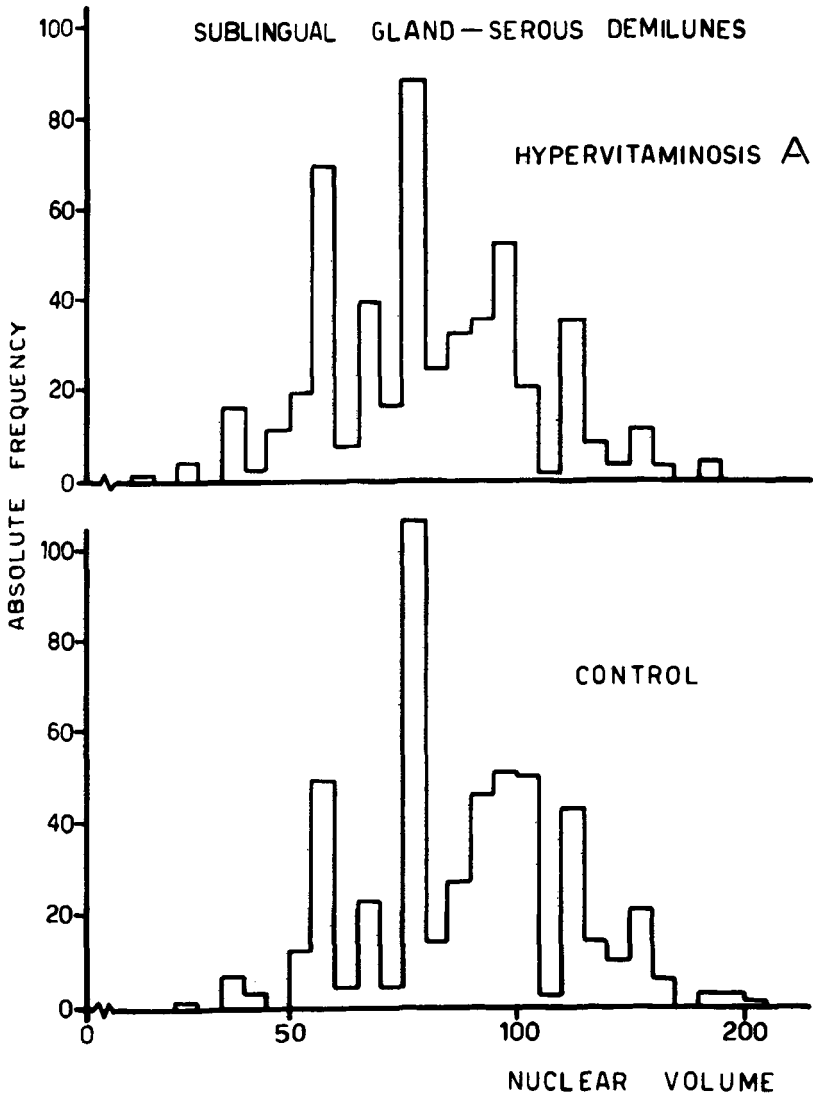


FIGURE 2

Absolute frequency of the logarithms of the nuclear volume of demilune cells for hypervitaminotic and control animals

TABLE 3

**NUCLEAR VOLUME FREQUENCY OF THE SUBLINGUAL  
DEMILUNE CELLS OF CONTROL AND TREATED ANIMALS**

|  | Control    | Treated    | Total        |
|--|------------|------------|--------------|
| Values lower than the median               | 209        | 272        | 481          |
| Values higher than, or equal to the median | 291        | 228        | 519          |
| <b>Total</b>                               | <b>500</b> | <b>500</b> | <b>1,000</b> |

### DISCUSSION

Histological examination of the sublingual gland of our vitamin A-treated animals showed smaller size acini with lower cells and smaller nuclei. The serous demilunes showed smaller cells and nuclei. The striated ducts also showed lower cells and smaller nuclei, as well as disorganization. The histological aspect is similar to those observed in other salivary glands by Lopes *et al.* (4, 5) and Petenusci *et al.* (2). The presence of degenerating cells in a hyperactive gland may be an indication of premature cellular death due to excessive synthesis followed by exhaustion. Our morphometric results confirm this possibility, since the data obtained by the Chalkley technique (6) revealed that vitamin A provoked decreased acini and ducts and increased connective tissue in the sublingual gland. These morphometric data were confirmed when the acinar areas were measured in the glands of treated animals and found to be smaller in relation to the controls. The smaller nuclei observed histologically in the hypervitaminotic animals were also evaluated by the karyometry technique and found to be smaller in treated than in control animals both in the serous demilune and the striated duct cells. This fact was interpreted as a sign of hyperactivity followed by exhaustion in the glands of the treated animals.

The following may be a reasonable explanation for this phenomenon of hyperactivity followed by degeneration and premature cellular death due to excessive synthesis and exhaustion: there is ample evidence that vitamin A directly influences the function of the adrenal glands (9, 10) and that a relationship

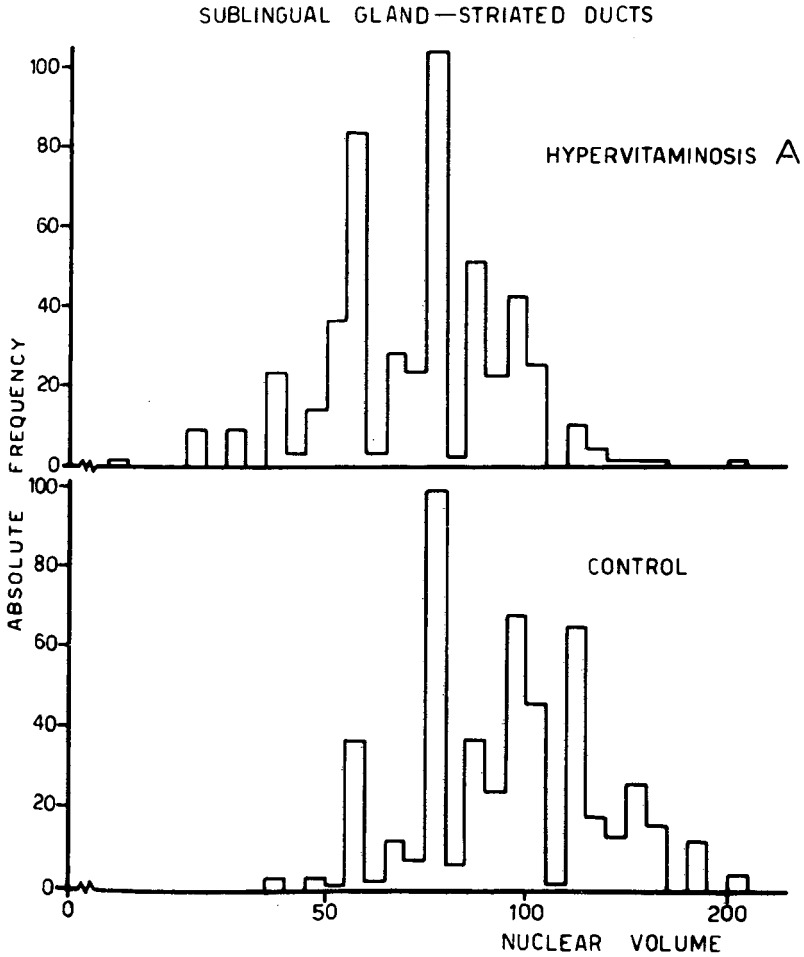


FIGURE 3

Absolute frequency of the logarithms of the nuclear volume of duct cells for hypervitaminotic and control animals

TABLE 4

**NUCLEAR VOLUME FREQUENCY OF THE SUBLINGUAL  
STRIATED DUCT CELLS OF CONTROL AND TREATED ANIMALS**

|  | Control    | Treated    | Total        |
|--|------------|------------|--------------|
| Values lower than the median               | 65         | 237        | 302          |
| Values higher than, or equal to the median | 435        | 263        | 698          |
| <b>Total</b>                               | <b>500</b> | <b>500</b> | <b>1,000</b> |

exists between membrane permeability and adrenal gland hormones. Thus, excess doses of vitamin A provoke increased cell and organelle permeability (see review in 11) and affect the tissue through the adrenal gland (12-14). It has been well established that vitamin A affects the structural stability of lysosomes (15), and that, on the other hand, corticosteroids protect the lysosomes from disintegration (16).

On the basis of all these reports, as well as of adrenal hypertrophy (also observed in our material), Ram & Misra (14) suggest that the effect of excess vitamin A administered to rats is mediated by stimulation of adrenal activity in corticosteroid synthesis. These authors suggest that vitamin A, on the one hand, affects the stability of lysosomes membranes and, on the other, stimulates the synthesis of corticosteroids which protect the lysosomes from disintegration. At low vitamin A doses, these effects compensate each other; at excessive or prolonged doses, however, stimulation of adrenal hyperactivity may not be proportional to the labilizing action of vitamin A on the lysosomes membrane. Consequently, with hydrolase release, degradation of the respective substrates may occur, with a reduction in their amounts.

#### RESUMEN

#### ESTUDIO MORFOMETRICO DEL EFECTO DE LA HIPERVITAMINOSIS A SOBRE LA GLANDULA SUBLINGUAL DE LA RATA

La administración de vitamina A en exceso induce las siguientes altera-

ciones en la glándula sublingual de la rata: acinos de menor tamaño y núcleos de menor volumen, las semilunas serosas mostraron células y núcleos menores; los ductos estriados evidenciaron células menores y desorganizadas, y los núcleos eran de menor volumen. Estos datos fueron confirmados por técnicas morfométricas.

### BIBLIOGRAPHY

1. Regezi, J. A. & N. H. Rowe. Morphologic effects of hypervitaminosis A on rat submandibular gland. *Arch. Oral Biol.*, 17: 1609-1618, 1972.
2. Petenusci, S. O., R. A. Lopes, C. R. Silva Netto & G. Maia Campos. Contribuição ao estudo dos efeitos da hipervitaminose A nas glândulas salivares e adrenal do rato. *Rev. Fac. Farm. Odont. Ribeirão Preto*, 13: 35-40, 1976.
3. Lopes, R. A., R. Azoubel, V. Valeri, S. Iucif & L. C. Gosuen. Morphologic effects of hypervitaminosis A on rat sublingual glands. *J. Dent. Res.*, 53: 757, 1974.
4. Rosa, R., M. L. Grieco & J. Nicolau. The effect of hypervitaminosis A on the sialic acid and hexosamine contents of the salivary glands of rats. *Internat. J. Vit. Nutr. Res.*, 46: 369-372, 1976.
5. Lopes, R. A., G. Maia Campos, V. Valeri, S. Iucif & R. Azoubel. Morphologic effects of hypervitaminosis A on posterior lingual salivary glands of the rat. *Rev. Fac. Farm. Odont. Ribeirão Preto*, 10: 23-30, 1973.
6. Chalkley, H. W. Method for the quantitative morphologic analysis of tissues. *J. Nat. Cancer Inst.*, 4: 47-54, 1943.
7. Valeri, V., A. R. Cruz, J. S. H. Brandão & L. A. Lison. Relationship between cell nuclear volume and deoxyribonucleic acid of cell of normal epithelium, of carcinoma *in situ* and of invasive carcinoma of the uterine cervix. *Acta Cytol.*, 11: 488-496, 1967.
8. Siegel, S. *Nonparametric Statistics for the Behavioral Sciences*, New York, McGraw-Hill, 1956.
9. Selye, H. Sensitization of the skeleton to vitamin A overdose by cortisol. *Arthritis Rheum.*, 1:87, 1958.
10. Giroud, A. & A. R. Ratsimananga. Cortico-surrénale et déficiences vitaminiques. In: *Congrès de Nutrition et Glandes Endocrines*, Paris, B 105-B 132, 1960.
11. Dingle, J. T. & J. A. Lucy. Membrane phenomena in relation to vitamin A. *Proc. Nutr. Soc.*, 24: 170-172, 1965.
12. Mathur, A. R., R. Ramanathan & U. K. Misra. Effect of feeding excess of vitamin A and vitamin C on liver, plasma and adrenal lipids of rats.

- Internat. J. Vit. Nutr. Res.**, 44: 19-25, 1974.
13. Misra, U.; K. & N. Srivastava. Stimulation of cholesterologenesis by ascorbic acid in adrenal of rats fed vitamin A. **Internat. J. Vit. Nutr. Res.**, 44: 230-233, 1974.
  14. Ram, G. C. & U. K. Misra. Studies on mode of action of vitamin A. **Internat. J. Vit. Nutr. Res.**, 45: 3-19, 1975.
  15. Roels, O. A., O. R. Anderson, N. S. T. Lui, D. O. Shah & M. E. Trout. Vitamin A and membranes. **Am. J. Clin. Nutr.**, 22: 1020-1032, 1969.
  16. De Duve, C. & R. Wattiaux. Functions of lysosomes. **Ann. Rev. Physiol.**, 28: 435-492, 1966.